



For reprint orders, please contact:
reprints@futuremedicine.com

CRM197: reduction of atherosclerotic stenoses in carotids of three elderly patients

Silvio Buzzi^{1†},
Giorgio Buzzi²,
Anna Maria Buzzi³ &
Sauro Martini⁴

[†]Author for correspondence
¹TRIS Medical Center, via
G Felisatti 49, 48100,
Ravenna, Italy
Tel.: +39 544 318 06;
Fax: +39 544 318 06;
E-mail: silviobuzzi@
racine.ra.it

²Ospedale SM Croci, Italy
Tel.: +39 544 212 399;
Fax: +39 544 212 399;
E-mail: gbuzzi@linknet.it

³Ospedale Umberto I,
Lugo, Italy

⁴Casa di Cura, San
Francesco, Ravenna, Italy
Tel.: +39 544 458 410;
Fax: +39 544 458 410;
E-mail: dr.martinisauro
@libero.it

Background: Many years ago, diphtheria toxin was shown to exert an antitumor effect in mice and humans. However, these old studies suggested that the molecule, expected to affect cancer with its toxicity only, could also act through an immunological mechanism. In recent years, this suggestion has been reappraised and crossreacting material (CRM)197 administered to advanced cancer patients has shown encouraging results. CRM197 is a nontoxic mutant of diphtheria toxin that cross-reacts immunologically with the native counterpart. Unexpectedly, a cancer patient treated with this molecule obtained, along with a small shrinkage of his lung tumor, a 27% reduction of an atherosclerotic stenosis of his internal right carotid. We were amazed at this result since we knew that the only drugs useful against atherosclerosis were statins. **Objective:** This study aimed at investigating whether CRM197 may also affect atherosclerotic stenosis. **Patients & methods:** Three elderly patients with moderate-to-severe carotid stenoses and a poor performance status consented to undergo an experimental treatment with CRM197. Patients were preliminarily examined for their immunocompetence against diphtheria toxin/CRM197. Two different doses were adopted: 1.7 mg/day for subjects lacking immunocompetence and 3.5 mg/day for subjects with immunocompetence. Treatment consisted of six subcutaneous injections of CRM197 administered in the abdominal wall on alternate days. A further dose (similar to the first) was administered six times, every 2 months. Side effects were unremarkable. The size of stenosis was evaluated periodically with careful ultrasound scan by the same operator. **Results:** Surprisingly, even assuming that the ultrasound monitoring of the size of stenosis may be slightly inaccurate, all patients demonstrated a very slow but striking stenosis reduction. The mechanism accountable for these results could be immunological in nature. **Conclusion:** Despite the fact that no firm conclusions can be drawn from this limited trial, the achieved results are undeniably very promising.

Many years ago, diphtheria toxin (DT) was shown to exert antitumor activity in mice and in humans [1,2]. However, while the molecule had been tested as an antitumor agent relying on its toxicity only, some observations suggested that its strong inflammatory-immunological property might also have had a role in achieving the antitumor effect [3,4].

On the basis of these observations, we performed three consecutive clinical trials to test the anticancer potential of crossreacting material (CRM)197 (58422 Mr), a nontoxic mutant of DT, between 1997 and 2004. CRM197 was obtained in the early 1970s from a strain of *Corynebacterium diphtheriae* lysogenized with a β -phage carrying a mutated *tox* gene. The molecule lacks any toxicity owing to a single glycine to glutamic acid change at position 52, while it is immunologically indistinguishable from DT and maintains the ability of the native counterpart to bind to a

specific cell membrane receptor [5]. The CRM197 receptor is heparin-binding epidermal growth factor (HB-EGF), a member of the superfamily of growth factors that competes for the EGF receptor. HB-EGF is overexpressed in the uterus during blastocyst implantation, in wound healing, in many tumors and in cells of the atherosclerotic plaque [6]. On the whole, the data obtained by administering CRM197 to advanced cancer patients were encouraging [7–9].

Atherosclerosis is one of the scourges of modern Western society and a cause of considerable morbidity and mortality. The process of atherogenesis consists partly of accumulation of lipids within the artery wall and mostly of vascular inflammation [10]. Nowadays, the only drugs that seem useful against this threatening disease are statins, a group of products that may decrease the level of cholesterol and exert an anti-inflammatory activity [11]. Statins affect atherosclerosis mainly by reducing the rate of its progression [12].

Keywords: carotid
atherosclerosis, CRM197,
diphtheria toxin,
immunological mechanism,
stenosis reduction

future
medicine part of fsg

Table 1. Patients' details and stenoses over time.

Patient no. (age/sex)	Immunity to CRM197	CRM197 (mg/day)	Stenosis % RIC	Stenosis % LIC	Stenosis % LCC
1 (84 years/F)	No	1.7	75 → 28*	50 → 18*	
2 (80 years/M)	No	1.7	48 → 0 [‡]	30 → 30 [§]	
3 (76 years/M)	Humoral and DTH	3.5	40 → 11*		68 → 5 [‡]

*Mixed plaque. [‡]Soft plaque. [§]Hard plaque.
 DTH: Delayed-type hypersensitivity; LCC: Left common carotid; LIC: Left internal carotid; RIC: Right internal carotid.

Our attention focused on the field of atherosclerosis after a casual observation made by our group in 1998 [13]. During the development of the third of our cancer trials, we treated a 68-year-old man, suffering from an inoperable lung carcinoma, with CRM197 (he had been previously operated for a colon cancer and a laryngeal cancer). The patient achieved a surprising result. In fact, along with a minimal shrinkage of his lung tumor, he presented with a 27% reduction in atherosclerotic stenosis of the right internal carotid. This result amazed and intrigued us to such an extent that we eventually decided to investigate this phenomenon further.

The present work was carried out specifically to test the attractive hypothesis that CRM197, besides its antitumor activity, might also affect atherosclerotic plaques.

Patients & methods

Mindful of the oncologic patient that had experienced a considerable size reduction of a carotid stenosis after treatment with CRM197 (lot CRM003, 20,000 Lf and 53.8 mg protein/ml),

we made a proposal to our Ethical Committee to treat a small number of consenting patients with this nontoxic product. The Committee approved our pilot project considering that CRM197 lacks toxicity.

Between February and October 2000, three unusual patients (one female and two male) presented at our office with carotid stenosis. Their ages ranged from 76 to 84 years. Owing to different reasons, all presented with a poor performance status. Two patients had received no treatment against atherosclerosis and one was taking a low dose of pravastatin. All patients had a history consistent with a progressive worsening of their carotid stenoses and none met the required criteria for vascular surgery. All patients accepted our proposed treatment and signed an informed consent.

Prior to enrolment, patients underwent a physical examination with documentation of performance status, electrocardiogram (ECG), routine biochemistry and urinalysis. Physical examination was repeated on alternate days throughout treatment. Routine biochemistry and urinalysis were repeated weekly during the first month and once a month thereafter. A complete blood count was performed before the first administration of CRM197, and 24 and 48 h later, to verify whether the molecule behaves like DT, which elicits leukocytosis [14]. Humans may present very different antibody titers against DT [15], therefore, we checked the pretreatment level of this antitoxin in all patients using an enzyme-linked immunosorbent assay (ELISA) method. Since many individuals may also acquire delayed-type hypersensitivity (DTH) to DT as a result of subclinical infections [16], we tested all patients by intradermally injecting 0.1 ml of phosphate-buffered solution (PBS), pH 7.2, containing CRM197 0.003 µg into the forearm. Positive DTH condition was measured by the appearance of an erythematous reaction of at least 1.0 cm in diameter within 24 h.

Figure 1. Left common carotid cross-section.

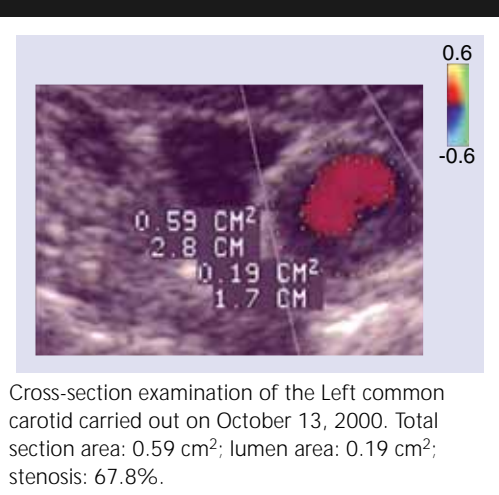
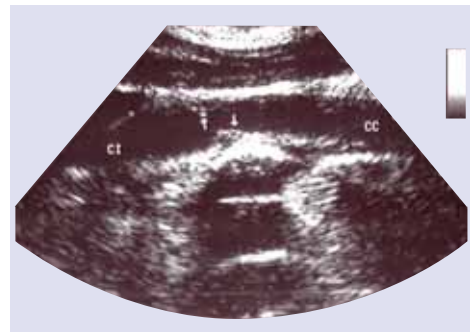


Figure 2. Left common carotid longitudinal section.

Longitudinal section of left common carotid carried out on December 5, 2001. Stenosis: 55%.

CRM197 was a gift from R Rappuoli, Chiron Vaccines (Siena, Italy). The product was diluted to a concentration of 432 $\mu\text{g/ml}$ in sterilized PBS (10 mM sodium phosphate buffered solution, pH 7.2) containing 10% sucrose as a stabilizer. The final preparation, tested for sterility and general safety on the depilated skin of young New Zealand rabbits, was aliquoted in pyrogen-free vials and stored at -20°C .

CRM197 was administered by six subcutaneous injections, on alternate days, in the abdominal wall. Since the molecule has a half-life ranging from 16 to 20 h [9], this schedule was chosen to prevent accumulation of the product in plasma and tissues. A further dose (similar to the first) was administered every 2 months, six times. Two dose levels, derived from our previous cancer trial, were adopted in this work: 1.7 mg/day for patients lacking immunocompetence against DT/CRM197 (≤ 0.01 IU/serum ml of antitoxin) and 3.5 mg/day for patients with immunocompetence against DT/CRM197 (>0.01 IU/serum ml of antitoxin) [9]. Patients were treated on an outpatient basis and they were periodically checked with a careful ultrasound scan by Sauro Martini. When the results of a patient's check-up showed no change from his previous visit, it was considered to be the final result. One patient was followed for approximately 5 years. Stenosis of internal carotids was measured using the NA-CET method.

Results

Patient 1

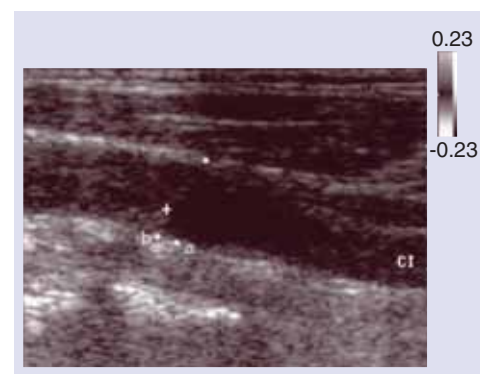
In February 2000, an 84-year-old woman presented at our office with a short disturbance of consciousness. She was moderately overweight

(body mass index: 26.6) with a negligible family history. She had no established risk factors consistent with cardiovascular disease. On physical examination, the patient revealed a strong bilateral carotid bruit. Total and low-density lipoprotein (LDL) cholesterol were 280 and 196 mg/dl, respectively. The ELISA test and the intradermal test showed no immunocompetence to DT/CRM197. Other routine blood tests and ECG were normal. Sonography evidenced 75% stenosis (mixed plaque) of the right internal carotid (RIC) and 50% stenosis (mixed plaque) of the left internal carotid (LIC). A vascular surgeon advised the patient against any project of endarterectomy, primarily owing to her advanced age.

CRM197 treatment (1.7 mg/day) was started in March 2000. At 24 h after the first injection, the number of circulating neutrophils increased by 30%. At 4 weeks after the start of the treatment, the levels of total and LDL cholesterol had not significantly changed. No evident side effect was detected. Afterward, both stenoses began to decrease slowly. In October 2001, the stenosis of RIC and that of LIC were reduced to 28 and 18%, respectively (Table 1). The patient is still alive and well, as of April 2007.

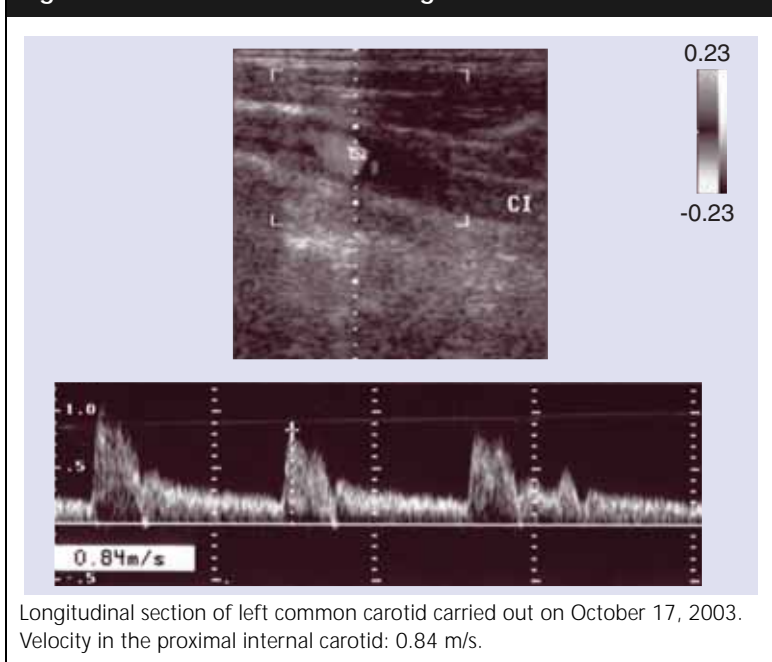
Patient 2

In July 2000, an 80-year-old man was seen owing to two unexplained episodes of a sudden fall to the ground. The family history disclosed that both of his parents died of stroke. He had palsy of the right facial nerve and right deafness as a consequence of a skull fracture suffered during a road accident. A computerized

Figure 3. Left common carotid longitudinal section.

Longitudinal section of left common carotid carried out on October 17, 2003. (a) Vessel diameter; (b) Plaque diameter; stenosis: 35%.

Figure 4. Left common carotid longitudinal section.



tomography scan showed a moderate degree of cerebral atrophy, and an examination by a cardiologist was normal. On physical examination, a bruit was heard on the left carotid of the patient. Total and LDL cholesterol were 245 and 159 mg/dl, respectively. ELISA and intradermal tests showed no immunocompetence to DT/CRM197. Routine blood tests were normal, except for alanine aminotransferase levels, which were 52 IU/l (normal range: 10–30 IU/l). Sonography evidenced 48% stenosis (soft plaque) of RIC and 30% stenosis (hard plaque) of LIC.

Treatment (1.7 mg/day) was initiated in July 2000. At 24 h after the first injection, the number of circulating neutrophils of the patient increased by 20%. At 4 weeks after initiation of treatment, the levels of total and LDL cholesterol had not significantly changed. No evident side effect was detected. The stenosis of RIC had a slow and progressive reduction. In August 2004, RIC evidenced only thickening of the intima, while LIC was unchanged (Table 1). The patient is still alive, as of April 2007.

Patient 3

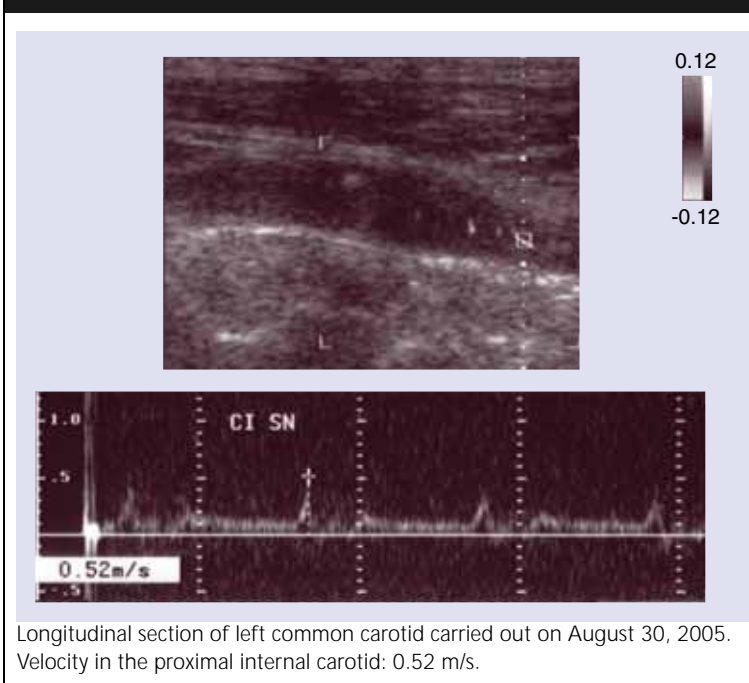
In October 2000, a 76-year-old man came to our office complaining of worsening carotid stenoses. In 1998, he had suffered a left retinal stroke and had undergone a carotid sonography. The examination showed that his RIC

and his left common carotid (LCC) had mild-to-moderate atherosclerotic stenosis. A physician ordered the patient pravastatin (20 mg/day) and aspirin (100 mg/day). Pravastatin had been taken regularly, while aspirin had been stopped after 2 months owing to gastric bleeding. In turn, ticlopidine, which replaced aspirin, had been discontinued due to an allergic rash. On physical examination, the patient evidenced a mild right parkinsonism and an old paracentral scotoma of the left retina. Total and LDL cholesterol were 232 and 150 mg/dl, respectively. The ELISA test evidenced a good level of humoral immunity to DT/CRM197 (0.03 IU/serum ml of anti-toxin) and the intradermal test detected a weak DTH to DT/CRM197. Routine blood tests and ECG were normal. Sonography showed 40% stenosis of RIC (mixed plaque) and 68% stenosis of LCC (soft plaque). LIC and right common carotid showed only thickening of the intima.

Treatment (3.5 mg/day) was started in October 2000. At 24 h after the first injection, the number of circulating neutrophils of the patient increased by 55%. At 4 weeks after initiation of treatment, the levels of total and LDL cholesterol had not significantly changed. The only side effects were erythematous and an itching skin reaction in the injection sites. A slow and progressive decrease in size of both carotid lesions and vessel areas was detected over time. Although the LCC lesion was not hemodynamic, velocity in proximal LIC decreased gradually. At 58 months after the initiation of treatment, the RIC stenosis was 11% and that of LCC was 5% (Table 1). Some carotid records of this patient are shown in the images of Figures 1–6. The images were obtained with two different instruments: Apogee CX[®] (Figures 1 & 2) and Apogee 800 Plus (Figures 3–6). Both the instruments were endowed with a 7.5 MHz linear probe. The patient is still alive and well as of April 2007.

Discussion

The pathogenetic mechanism of atherosclerosis includes the level of plasma lipoproteins, mainly that of LDL cholesterol, and a notable inflammatory component [10]. This latter joint cause, implying an increased activity by T cells, caused some immunologists to suggest that atherosclerosis might be added to the list of organ-specific autoimmune diseases [11]. Currently, to counteract this disease, the preferred

Figure 5. Left common carotid longitudinal section.

(or only) drugs are statins. The present work was carried out to investigate whether CRM197 may be added to statins in the fight against atherosclerosis.

Actually, besides the casual observation we made on a cancer patient, there are also some theoretical reasons to support the idea that the molecule might contrast the plaque. For instance, it was recently reported that CRM197 exerted an encouraging activity against cancer [7–9], a disease mainly characterized by uncontrolled cell proliferation. Similarly, it is well known that atherosclerosis presents a slow, but uncontrolled, proliferation of smooth muscle cells (SMCs) in affected vessels. Furthermore, it is meaningful that both cancer and vascular SMCs of the plaque overexpress HB-EGF, a growth factor that also acts as the specific cell membrane receptor for DT/CRM197. HB-EGF of activated SMCs might represent a very attractive target for CRM197. In fact, this growth factor seems to be implicated in migration and proliferation of SMCs during the formation of the plaque [6]. Finally, since atherosclerosis might be inclined to autoimmunity [11], it would be important to fight its lineage of activated SMC that is the most responsible for the self-feeding of the disease.

Our pilot trial achieved an unexpected reduction of artery stenoses. However, we are aware of the limitations of the trial, especially since we monitored the patients with an ultrasound scan, results for which can be misinterpreted in the absence of a skilled technician. In addition, the mechanism of action of the molecule appears quite mysterious but might be provisionally answered by the following hypothesis: the binding of a strong bacterial antigen, such as CRM197, to SMCs can provoke responses from antibodies and cells of natural and acquired immunity that cross-react with the microbial antigen and a self antigen of SMCs. The subsequent inflammatory-immunological reaction might slowly erode the plaque.

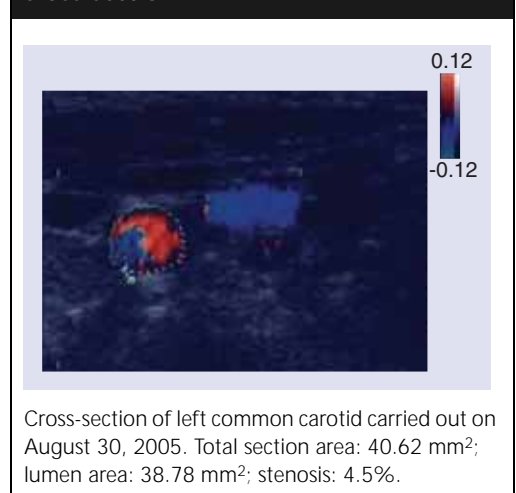
We therefore propose a future trial endowed with a more reliable monitoring method (e.g., magnetic resonance imaging at high resolution).

Conclusion

A casual observation made on a cancer patient treated with CRM197 prompted us to test the molecule against the atherosclerotic plaque. The trial achieved a surprising reduction in artery stenoses. It is conceivable that the mechanism underlying these results is immunological in nature.

Conflict of interest

We declare that we have no conflicts of interest.

Figure 6. Left common carotid cross-section.

Executive summary

- Atherosclerosis is one of the scourges of modern Western society and a cause of considerable morbidity and mortality.
- An effective regression therapy for atherosclerosis has not yet been found.
- Currently, statins are the preferred drugs for atherosclerosis. They can affect the disease only by reducing the rate of its progression.
- Crossreacting material (CRM)197 is a nontoxic mutant of diphtheria toxin and shares its immunological properties and its ability to bind to a cell membrane receptor.
- The CRM197 receptor is heparin-binding epidermal growth factor (HB-EGF). HB-EGF is overexpressed in many tumors and in atherosclerotic plaques.
- Recently, we hypothesized that the overexpression of HB-EGF in cancer might allow preferential binding of CRM197 to malignant cells with a subsequent inflammatory-immunological reaction affecting the tumor. Three consecutive clinical trials were consistent with this hypothesis.
- During an antitumor trial with CRM197 performed in advanced cancer patients, a man with a lung carcinoma had a surprising reduction in size of a carotid stenosis.
- This case prompted us to perform a pilot trial with CRM197 on three elderly patients complaining of carotid stenoses and poor performance status.
- The treatment with CRM197 had unremarkable side effects. After the first subcutaneous injection, the patients had an increase in the number of circulating neutrophils. All the patients had a slow but striking reduction in their stenoses depending on soft and mixed plaque.

Bibliography

1. Buzzi S, Maistrello I: Inhibition of growth of Ehrlich tumors in Swiss mice by diphtheria toxin. *Cancer Res.* 33, 2349–2353 (1973).
2. Buzzi S: Diphtheria toxin treatment of human advanced cancer. *Cancer Res.* 42, 2054–2058 (1982).
3. Buzzi S, Buzzi L: Cancer immunity after treatment of Ehrlich tumor with diphtheria toxin. *Cancer Res.* 34, 3481–3486 (1974).
4. Buzzi S: Diphtheria toxin in cancer therapy. *Lancet* 1, 628–629 (1974).
5. Rappuoli R: New and improved vaccines against diphtheria and tetanus. In: *New Generation Vaccines*. Woodrow GC, Levine MM (Eds). Marcel Dekker, NY, USA 251–254 (1990).
6. Raab G, Klagsbrun M: Heparin-binding EGF-like growth factor. *Biochim. Biophys. Acta* 1333, 179–199 (1997).
7. Buzzi S, Baccini C, Rubboli D, Monti G, Buzzi G, Buzzi AM: Phase I–II study of CRM197 administration to 50 advanced cancer patients. *Proceedings of AACR-NCI-EORTC International Conference*. Washington DC, USA, November 16–19, 1999 (Abstract 384).
8. Buzzi S, Rubboli D, Buzzi G, Buzzi AM, Morisi C, Pironi F: CRM197 and cancer: effects of intratumoral administration. *Therapy* 1(1), 61–66 (2004).
9. Buzzi S, Rubboli D, Buzzi G, Buzzi AM, Morisi C, Pironi F: CRM197 (non-toxic diphtheria toxin): effects on advanced cancer patients. *Cancer Immunol. Immunother.* 53, 1041–1048 (2004).
10. Ross R: Atherosclerosis – an inflammatory disease. *N. Engl. J. Med.* 340(2), 115–126 (1999).
11. Ehrenstein MR, Jury EC, Mauri C: Statins for atherosclerosis – as good as it gets? *N. Engl. J. Med.* 352(1), 73–75 (2005).
12. Nissen SE, Tuzcu EM, Schoenhagen P *et al.*: Statin therapy, LDL cholesterol, C-reactive protein, and coronary artery disease. *N. Engl. J. Med.* 352 (1), 29–38 (2005).
13. Ross R: The pathogenesis of atherosclerosis: a perspective for the 1990s. *Nature* 362, 801–809 (1993).
14. Harnisch JP: Diphtheria. In: *Harrison's Principles of Internal Medicine (9th Edition)*. Isselbacher KJ, Adams RD, Braunwald E, Petersdorf RG, Wilson ID (Eds). McGraw-Hill, NY, USA 671 (1980).
15. Wirtz M, Puccinelli M, Mele C, Gentili G: Immunity to diphtheria in the 4–70 year age group in Italy. *Vaccine* 13, 771–773 (1995).
16. Davis BD, Dulbecco R, Eisen HN, Ginsberg HS, Wood WB: *Microbiology*. Harper & Row, NY, USA 676 (1968).